

Surgical Correction of Maxillary Protrusion by Ostectomy and Osteotomy

by

G. C. BARTLETT

*Department of Dental Surgery, University of Ceylon,
Peradeniya*

Maxillary protrusion apart from giving rise to an unaesthetic appearance is usually associated with mouth breathing. Mouth breathing interferes with normal development of the maxillae, predisposing to infections of the gums, tonsils and adenoids. In children, orthodontics is the treatment of choice for this condition. In adults, the usual method of correction is extraction of the anterior teeth, trimming down the alveolus and the fitting of a partial denture. During the past decade surgical correction of this deformity has been carried out in Switzerland, Sweden, the United States and England with success (Murphey and Walker, 1963; Winstanley, 1965). The author had the privilege of having this procedure demonstrated to him by Professor Obwegeser and his staff at Zurich and in addition seen case records of Docent Hogeman of the Department of Plastic Surgery in Malmo, Sweden. This paper describes a successful correction of maxillary protrusion by ostectomy and osteotomy, a surgical procedure which has not been reported in Ceylon. ◦

Case Report

Patient was a well built medical student in his early twenties, in normal health. He had been in the habit of sucking his thumb from boyhood till adolescence. As shown in fig. 1 he had protruding upper incisor teeth which were drawn well over the lower lip interfering with speech and mastication. Figure 2 shows the X ray of the skull of the subject. The lower incisors were over-erupted impinging on the palatal mucosa (figure 3). The patient was deeply concerned about his general appearance and came to the Dental School to have his front teeth extracted and replaced with a denture. When it was explained to him that the deformity could be surgically rectified without the extraction of his incisor teeth, he readily agreed to surgical correction.

The following preoperative procedures were carried out.

- (1) X rays—Lateral view of facial skeleton.
Intra oral views.
- (2) Photographs—Full face and profile.
- (3) Study models of dental arches.

The models were mounted on an articulator and with the aid of a fretsaw the 4/4 region along with a strip about 4 mm. wide was excised from the vault. Each palatal cut on each side was made posteriorly and medially as shown in fig. 4. This portion was removed from the model and the anterior portion of the model carrying 321/123 was pushed back by about 4 mm. and rotated downwards to correct the protrusion and proclination. The anterior segment was fixed in its new position with the rest of the upper model, using sticky wax and later reinforced with addition of stone mix over the site of union. A cast metal splint with connecting bars on either side in the 4/4 region was constructed.

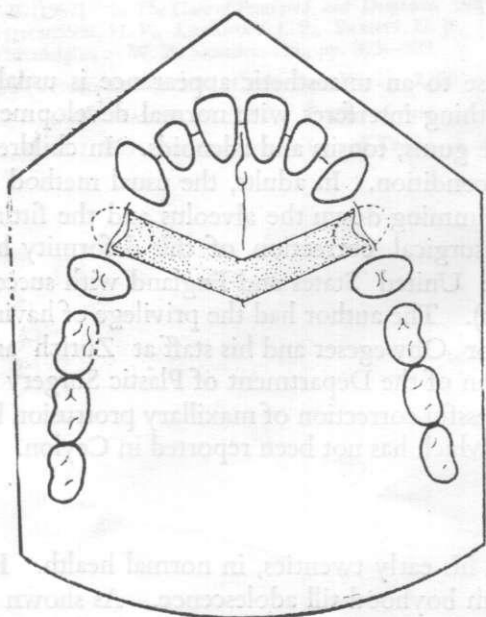


Fig. 4

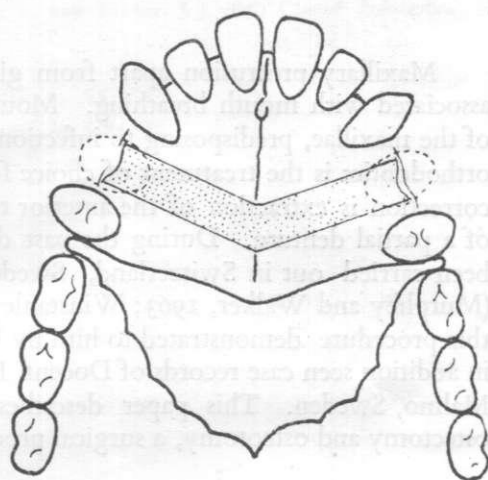


Fig. 5

Operation Stage 1

Under endotracheal anaesthesia (halothane, nitrous oxide and oxygen) the 4/4 were extracted. The palatal mucosa was stripped from the bone and a width of bone approximately 4 mm. was removed with the aid of burrs and osteotomes. The cut sweeping back into the vault of the palate and meeting about the middle at an angle, care having been taken to preserve the nasal epithelium overlying the bony palate. The alveolus 4/4 region was also cut as far laterally as possible (see fig. 5); the palatal mucosa then sutured back into position. After a period of about six weeks Stage 2 operation was performed. This interval was allowed for the re-establishment of the blood supply to the anterior segment.

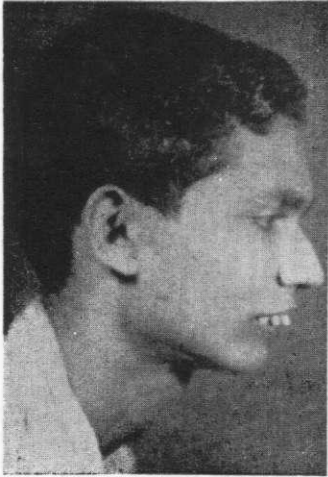

Fig. 1

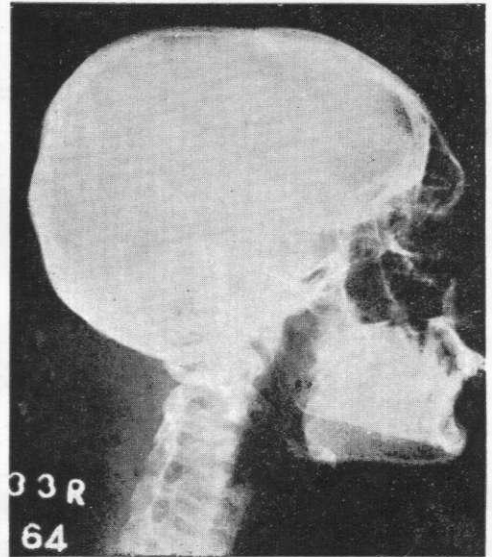


Fig. 2

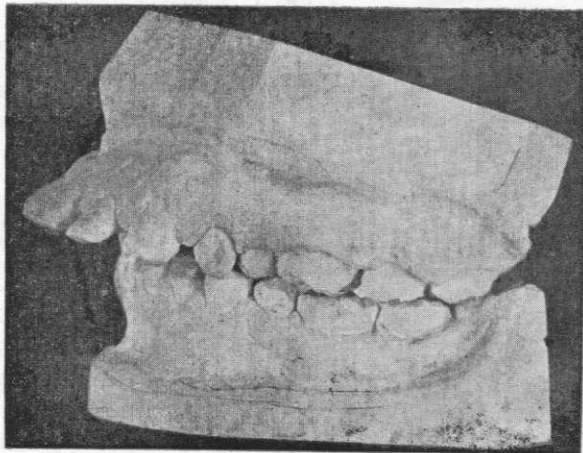


Fig. 3

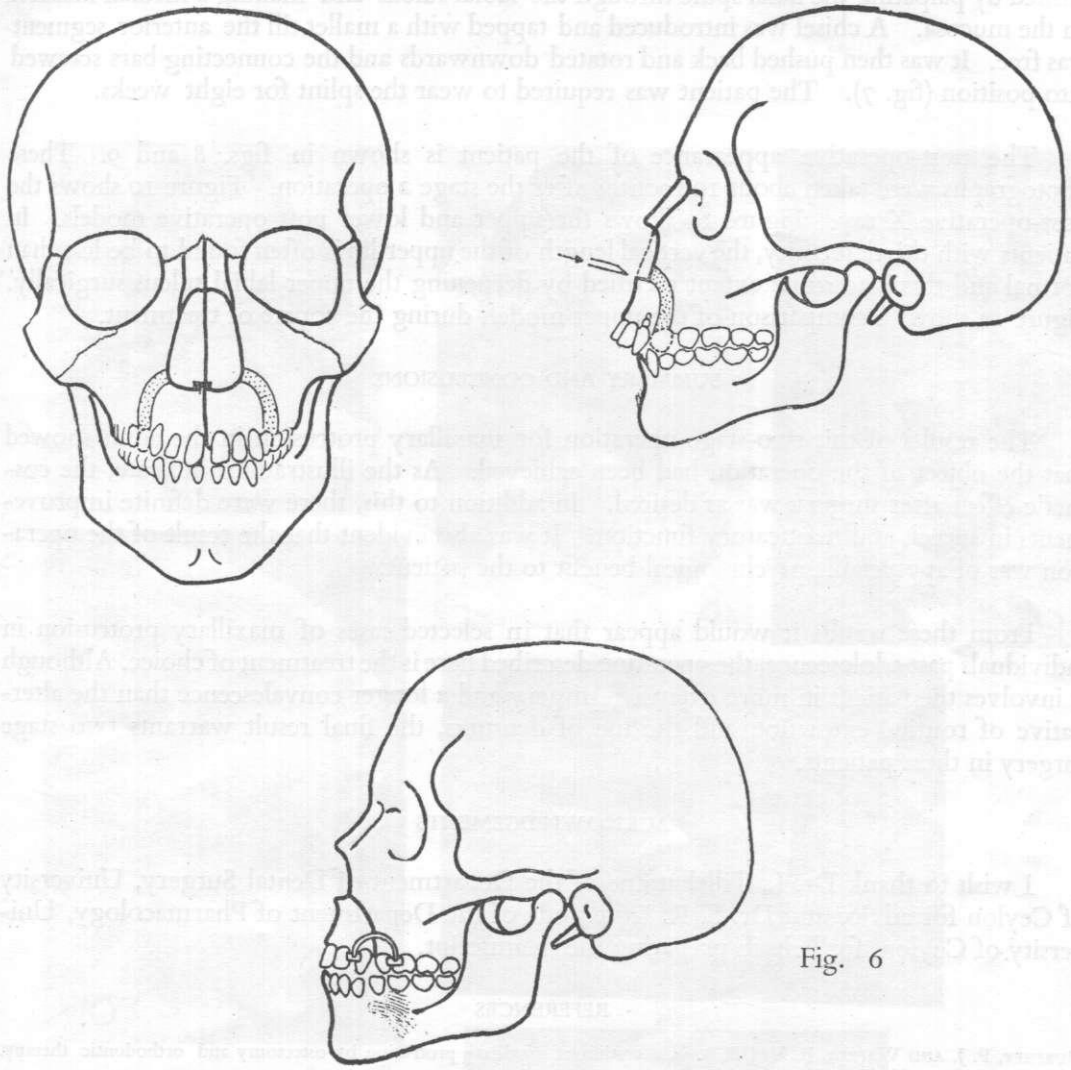


Fig. 6

Operation Stage 2 (see fig. 6)

Prior to the operation the three piece splint was cemented on the teeth with copper cement. Under endotracheal anaesthesia a slightly oblique incision with an inclination forward was made just distal to the 4 region on the labial side of the gingiva. The muco-periosteum was reflected and retracted till the corresponding lateral margin of the pyriform aperture of the nose came into view. The bone was cut from the 4 region passing forwards over the apices of the canines to the lateral margin of the pyriform aperture (fig. 6). About 4 mm. width of bone was removed along the line of section. The same procedure was adopted on the opposite side. To free the anterior segment of the maxilla completely, the septum was separated from the nasal fossa. This was accom-

plished by palpating the nasal spine through the labial sulcus and making a median incision on the mucosa. A chisel was introduced and tapped with a mallet till the anterior segment was free. It was then pushed back and rotated downwards and the connecting bars screwed into position (fig. 7). The patient was required to wear the splint for eight weeks.

The post-operative appearance of the patient is shown in figs. 8 and 9. These photographs were taken about 10 months after the stage 2 operation. Figure 10 shows the post-operative X ray. Figure 11 shows the upper and lower post operative models. In patients with this deformity, the vertical length of the upper lip is often found to be less than normal and this is to some extent rectified by deepening the upper labial sulcus surgically. Figure 12 shows a comparison of the upper models during the course of treatment.

SUMMARY AND CONCLUSIONS

The results of this two-stage operation for maxillary protrusion in the adult showed that the object of the operation had been achieved. As the illustrations indicate, the cosmetic effect after surgery was as desired. In addition to this, there were definite improvements in speech and masticatory function. It was also evident that the result of the operation was of appreciable psychological benefit to the patient.

From these results it would appear that in selected cases of maxillary protrusion in individuals past adolescence, the operation described here is the treatment of choice. Although it involves the patient in more extensive surgery and a longer convalescence than the alternative of routine extraction and the use of dentures, the final result warrants two stage surgery in these patients.

ACKNOWLEDGEMENTS

I wish to thank Dr. L. Tillekaratne of the Department of Dental Surgery, University of Ceylon for advice and Dr. S. R. Kottegoda of the Department of Pharmacology, University of Ceylon, for help in preparing the manuscript.

REFERENCES

- MURPHEY, P. J. AND WALKER, R. V. (1963). Correction of maxillary protrusion by ostectomy and orthodontic therapy. *J. oral. Surg.*, **21**, 275—290. (read in abstract).
- WINSTANLEY, R. P. (1965). One stage maxillary ostectomy for correction of class II division I malocclusion. *Brit. J. oral Surg.*, **2**, 173—178.

EXPLANATION OF PLATES

PLATE I

- Fig. 1. Preoperative photograph.
 Fig. 2. Preoperative X ray.
 Fig. 3. Upper and lower models preoperative.

PLATE II

- Fig. 7. Splint with connecting bars applied soon after Stage II operation.
 Fig. 8. Post operative photograph.
 Fig. 9. Post operative photograph.
 Fig. 10. Post operative X ray.
 Fig. 11. Comparison of upper models during course of treatment.

