

See discussions, stats, and author profiles for this publication at: <https://www.researchgate.net/publication/387326564>

Effect of Sri Lankan Traditional Medicine and Ayurveda Management in Endometriosis & Adenomyosis – A Case Study

Article in *International Journal of AYUSH Case Reports* · December 2024

DOI: 10.70805/ija-care.v8i4

CITATIONS

0

READS

9

3 authors:



Kaumadi Karunagoda

University of Colombo

62 PUBLICATIONS 69 CITATIONS

[SEE PROFILE](#)



Krishani Deepthika

Gampaha Wickramarachchi University of Indigenous Medicine

15 PUBLICATIONS 2 CITATIONS

[SEE PROFILE](#)



Pathirage Kamal Perera

University of Colombo

240 PUBLICATIONS 550 CITATIONS

[SEE PROFILE](#)

Effect of Sri Lankan Traditional Medicine and *Ayurveda* Management in Endometriosis & Adenomyosis: A Case Study

Kaumadi Karunagoda^{1*}, S. H. K. Deepthika,² PK Perera,³ YAUD Karunarathne⁴

¹ Professor, Department of Ayurveda Surgery, ENT, Ophthalmology and Gynecology, Obstetrics and Pediatrics, Faculty of Indigenous Medicine, University of Colombo, Sri Lanka.

² Lecturer, Department of Kaumarabhritya and Stree Roga, Faculty of Indigenous Medicine, Gampaha Wickramarachchi University of Indigenous Medicine, Sri Lanka.

³ Professor, Faculty of Indigenous Medicine, University of Colombo, Sri Lanka.

⁴ Senior Lecturer, Department of Ayurveda Surgery, ENT, Ophthalmology and Gynecology, Obstetrics and Pediatrics, Faculty of Indigenous Medicine, University of Colombo, Sri Lanka.

ABSTRACT:

Endometriosis affects about 10% of reproductive-age women and girls worldwide. Adenomyosis is a stage of the endometriosis where endometrial glands found deep within the myometrium. In this case study, a patient diagnosed with both endometriosis and adenomyosis with multiple endometrioma in right and left ovaries. She is a 42-year married nulliparous women without other pathologies. BMI-26.8, BP -120/78 mmHg and Pulse:78/min. History of laparoscopic Bi lateral cystectomy in year 2021. The intervention period was three months while the 1st drug regimen started by OPD management followed by two IPD treatment regimens in one month apart. *Sneha Sweda, Yoga Vasti, Nadi Sweda, Udara pattu, Mathra vasti* procedures were conducted with the 2nd and 4th oral drug regimen. In between 3rd drug regimen was continued at OPD level. The dysmenorrhea and dyspareunia were monthly assessed by using Visual Analog Scale (VAS). Before and after assessment of endometriomas and adenomyosis was measured by ultrasound scans conducted by the experts who are blind on the procedure. Other vital signs and menstrual pattern was observed ones in 2 weeks. After the treatments VAS score of dysmenorrhea was reduced to 0 from 10, pelvic pain from score 10 to 0 and of dyspareunia it reduced to 1 from 4. The ultrasound scan report proved the total disappearing of the endometrioma and adenomyosis after three months intervention. During the follow up period patients' quality of life (QOL) remained unchanged. In conclusion, endometriosis and adenomyosis can be successfully managed by Sri Lankan traditional and *Ayurveda* treatments.

KEYWORDS: Adenomyosis, Ayurveda, Endometriosis, Sri Lankan traditional medicine.

Received: 16.10.2024

Revised: 05.12.2024

Accepted: 15.12.2024

Published: 20.12.2024



Creative Commons Attribution-Non-Commercial-No Derivatives 4.0 International License

© 2024 International Journal of AYUSH Case Reports | Published by Tanaya Publication, Jamnagar.

Quick Response Code



*Corresponding Author:

Prof. Kaumadi Karunagoda

Professor, Department of Ayurveda Surgery, ENT, Ophthalmology & Gynecology, Obstetrics & Pediatrics, Faculty of Indigenous Medicine, University of Colombo, Sri Lanka

Email: kaumadi@fim.cmb.ac.lk

INTRODUCTION:

According to the WHO data sheet, endometriosis affects approximately 10% (190 million) of reproductive-age women and girls worldwide. It is a chronic disease characterized by severe, life-altering pain during periods, sexual intercourse, bowel movements and/or urine, persistent pelvic discomfort, stomach bloating, nausea, fatigue, and, in some cases, depression, anxiety, and infertility. Endometriosis has no known cure; thus, treatment focuses on symptom management.^[1] Surgical excision or destruction of endometriotic tissue is currently the primary treatment for pain and other symptoms in allopathic medicine, although symptoms recur in 40-45% of women, and 27% of women require surgery again within 5 years^[2]. Adenomyosis is a uterine pathology that is related closely to endometriosis. Both are oestrogen dependent disorders, which endometrial epithelial cells are ectopically present in myometrium. The symptoms of adenomyosis are similar to endometriosis^[3]. Conditions show similar pathogenesis and the clinical presentations to endometriosis and the adenomyosis described in ancient *Ayurveda* texts. Understanding the disease through *Ayurveda* aspect is important to design as well the explain the action of treatment line. *Vataja yoni vyapath* mentioned in *Ayurveda*; *Vatala Yoni Vyapad*, *Udavarta Yoni Vyapad* and *Paripluta Yoni Vyapada* can be closely correlated with Endometriosis and Adenomyosis conditions. The Retrograde menstruation or Sampson's theory which explain the regurgitate of menstrual blood patent fallopian tubes in to the peritoneal cavity^[4], where the implantation of these cells might occur was explained in *Udavarta Yoni vyapath*^[5]. The name of the disease; *Udavartha* itself describe the *Urdhvagamana* of *Raja*

(retrogration of Menstruation). General etiological factors of all gynecological disorders mentioned in *Ayurveda* can be equated to endometriosis and adenomyosis, such as in proper dietetics, in appropriate mode of life, Abnormalities of *Artava* and *Bija* and Curses or the previous deeds. In the first stage, the disease is manifested due to *Vimargagamana* of Vata dosha. Spread of endometrial tissues through implantation metaplasia and lymphatic blood born spread can be identify through *Vimargagamana*. In the second stage, the function of the ectopic endometrial tissues leads to inflammation. Hence at this stage *Pitta dosha* also involved with *Vata dosha* to initiate the *Paka*. After that due to inflammation scar tissues and adhesions formation happened with involvement of Kapha dosha. At the fourth stage shown widespread of ectopic endometrial tissues with many deep implants and thick adhesions. Hence this stage could be identified as *Tridoshaja* stage and may develop into malignant conditions.

In *Vatala Yoni Vyapath* and *Udavartha* similar symptoms were mentioned which can be related to endometriosis, such as dysmenorrhea, stiffness, roughness, and hyperesthesia. This common condition is controlled by certain herbal medicines effectively.^[6] Sri Lankan *Ayurveda* medicine also showcase certain positive results on endometriosis and adenomyosis related difficulties. There for considerable number of cases are attended to the clinic of *Ayurveda* gynecology and obstetrics professorial ward. Clinically encouraging results are observed but the scientific data is yet to be published. This study showed successful management on endometriosis and Adenomyosis through *Ayurveda* intervention. *Ayurveda* aspect of this condition is also discussed in this manuscript.

CASE REPORT:

This is a case report of a woman attended to the *Streeroga* clinic, *Streeroga Prasuthibantra* professorial unit of National *Ayurveda* Hospital, Sri Lanka. She is a 42-year-old, nulliparous, married woman with the complaint of dysmenorrhea, dyspareunia and pelvic pain condition for last 3 years. She was under subfertility treatments before with diagnosed bilateral ovarian endometrioma. Laparoscopic cystectomy and dye test was performed in year 2021. By that intervention two endometriomas were removed in both ovaries, adhesiolysis were done and bilateral tubal patency was confirmed. At that intervention bilateral fallopian tube patency was re-evaluated. Together with the results of histopathology endometriosis was confirmed.

After in November 2023, multiple Bilateral chocolate cysts; Largest right ovarian endometrioma 2 cm x 1.5 cm and largest left ovarian endometrioma, 1.8cm x 1cm was identified by the trans vaginal ultrasound scan. Also revealed an Adenomyotic uterus with 4 cm x 3 cm size Adenoma. Hence at that time she was diagnosed as Grade IV Endometriosis patient with Adenomyosis. Since December 2023 she starts *Ayurveda* treatments.

Menstrual History

Menarche: age of 11 years

Regular / Irregular: Irregular

Interval: >35days (Longest cycle length 42 days)

Duration: 7 days

Volume: Normal, two to three fully soaked pads used per day

Characters: Dark red, Clots+

Pain: Dysmenorrhea (VAS score 10), initiate before 2 to 3 days, get severe on 2nd day of cycle, reduce in 6th or 7th day. Associated with headache and pelvic pain.

Obstetric History

Married for 3 years, Gravida 0, Para 0, child 0 (G₀P₀C₀), No history of contraceptives.

General Examination

Height is 151cm, Weight is 66kg, BMI is 26.8kgm⁻². BP: 120/80mmHg, Pulse: 78/min, RR: 18/min. no other chronic illnesses.

Local Examination

Abdominal Examination – previous laparotomy scars were present, Deep tenderness was informed in the right iliac region and mildly tender in left iliac region. But no mass was palpated through abdomen. Vaginal Examination- Cervix healthy, Firm, no erosion, cervical and vaginal discharges are normal. Uterus anteverted. Deep tenderness was informed at bimanual palpation.

Patients Consent

Discussion was held with the patient regarding the available treatment options. Make her understand the health condition and consent was taken before starting the treatments. Written consent was obtained for the publishing her medical data without revealing the identity.

THERAPEUTIC INTERVENTION:

Treatment was continued for three months. Patient attend to OPD Treatments ones in two weeks. Within a three-month period, the patient was admitted to the ward two times for inward treatments where there was no menstruation. At that time, Panchakarma treatments and some *Sthanika cikitsa* / Local treatments were done with oral medicines. The detailed treatment plan is mentioned in table 1.

Assessment methods - Dysmenorrhea and dyspareunia were assessed by using Visual Analog Scale and follow up of the size of

cysts and progress of adenomyosis was done by ultrasound scans. Vital signs were monitored and recorded throughout the study period.

RESULTS

At the three months intervention period patient was well tolerated with the treatment. Clinical improvements were assessed monthly and the imaging study was done at the completion of 3rd months.

Table 1: Treatment protocol for the first month

Duration	Oral medicines	Local treatments	Pancakarma
1 st -2 nd weeks (OPD)	- <i>Pancamuli lagudraksha Kashaya</i> ½ cup bd - <i>Tripala Kwatha</i> 2 tablespoons Bd - <i>Candraprabha Vati</i> 2 bd - <i>Tripala churna</i> 5g nocte	<i>Stanika Sneha</i> - Heated <i>Sarshapadi</i> oil Abhyanga to Hypogastrium, left & right iliac region for 14 days after the menstruation	nil
3 rd – 4 th weeks (IPD)	- <i>Tripalguggul Kashaya</i> ½ cup bd - <i>Yogaraja guggulu</i> 2bd - <i>Nishadi churna</i> 5g bd - <i>Avipattikara churna</i> 5g bd	Day 1-12 <i>Stanika Sneha</i> - Heated <i>Sarshapadi</i> oil Abhyanga to Hypogastrium, left & right iliac region and back Day 1-12 <i>Nadi Sweda</i> - Lower abdomen and back Day 07-14 <i>Udara pattu</i> - Dashanga lepa+ <i>Sarshapadi</i> oil lower abdomen <i>Udvardana</i> : Lower abdomen with <i>Lekhanadi churna</i>	Day 3-12 <i>Yoga Vasti</i> (8 days) <i>Nirgundyadi</i> oil And <i>Lekhanadi Kashaya</i>

Table 2: Treatment protocol for the second month

Duration	Oral medicines	Local treatments	Pancakarma
5 th -8 th weeks (OPD Treatments)	- <i>Tripala kwatha</i> 2 tablespoons Bd - <i>Kancanara guggulu</i> 2 bd - <i>Nishadi churna</i> 5g bd - <i>Krishnajeeraka churna</i> 5g bd - <i>Tripala churna</i> 5g nocte	-	-

Table 3: Treatment protocol for the second month

Duration	Oral medicines	Local treatments	Pancakarma
9 th -10 th week (IPD, 2 nd round)	- <i>Punarnawashtaka Kashaya</i> ½ cup bd - <i>Kancanara guggulu</i> 2 bd - <i>Arogyavardani vati</i> 2 nocte - <i>Nishadi churna</i> 5g bd - <i>Krishnajeeraka churna</i> 5g bd - <i>Tripala churna</i> 5g nocte	Day 1-7 - <i>Sarvanga Sweda</i> - <i>sarshapadi</i> oil + <i>Nigrodha</i> , <i>Eranda Vasa sweda</i> Day 1-7- <i>Udara pattu</i> - <i>Krishnajeeraka churna</i> + <i>Sarshapadi</i> oil Day 8-14- <i>Stanika Sweda</i> - Heated <i>Sarshapadi</i> oil <i>Abhyanga</i> to	Day 8-14 <i>Matra Vasti</i> : <i>Nirgundyadi</i> oil 60 ml per day,

		Hypogastrium, left & right iliac region for 07 days <i>Nadi Sweda</i> : 7 days	
11 th – 12 th weeks (OPD Treatments)	- <i>Madhyashti nishayugma</i> Kashaya 1/2cup bd - <i>Kancanara guggulu</i> 2bd - <i>Arogyavardhani vati</i> 2bd - <i>Nisbadi churna</i> 5g bd - <i>Tripala churna</i> 5g nocte	Day 1 – 14- <i>Sarshapadi</i> oil <i>Abhyanga</i> : 14 days	

Table 4: Assessment Vital Data

Data	Before treatment	After treatment (end of 3 rd month)	Follow up phase (end of 5 th month)
BMI	26.8 Kgm ²	25.3 Kgm ²	25.5 Kgm ²
Pulse	78 /min	78 / min	76/min
Bood pressure	120/70mmHg	120/70 mmHg	120/80 mmHg
Respiratory rate	18/min	18/min	18/min

Table 5: Assessment VAS ratings for Dysmenorrhoea and Dyspareunia

Phase	Period	Dyemenorrhoea	Dyspareunia	Pelvic pain
Treatment phase	Before treatment	Score 10	Score 04	Score 10
	End of 1 st month	Score 0	Score 01	Score 06
	End of 2 nd month	Score 0	Score 01	Score 02
	End of 3 rd month	Score 0	Score 01	Score 00
Follow up phase	End of 4 th month	Score 0	Score 0	Score 00
	End of 5 th month	Score 0	Score 0	Score 00

Table 6: Assessment of ultrasound scan (Trance Vaginal) findings

Before treatment	After treatment
Bilateral ovarian cysts (Chocolate cysts) R/Largest: 2cmx1.5cm L/Largest: 1.8x1 cm Adenoma: posterior wall of uterus, size 4cmx3cm Adhesions- Both ovaries adhered to posterior wall of the uterus. Fatty Liver G. I	No pelvic or ovarian masses Uterus normal size No free fluid in POD No Endometriosis or Adenomyosis No Fatty liver Dominant follicle in right ovary (16.4mmx11.4mm)

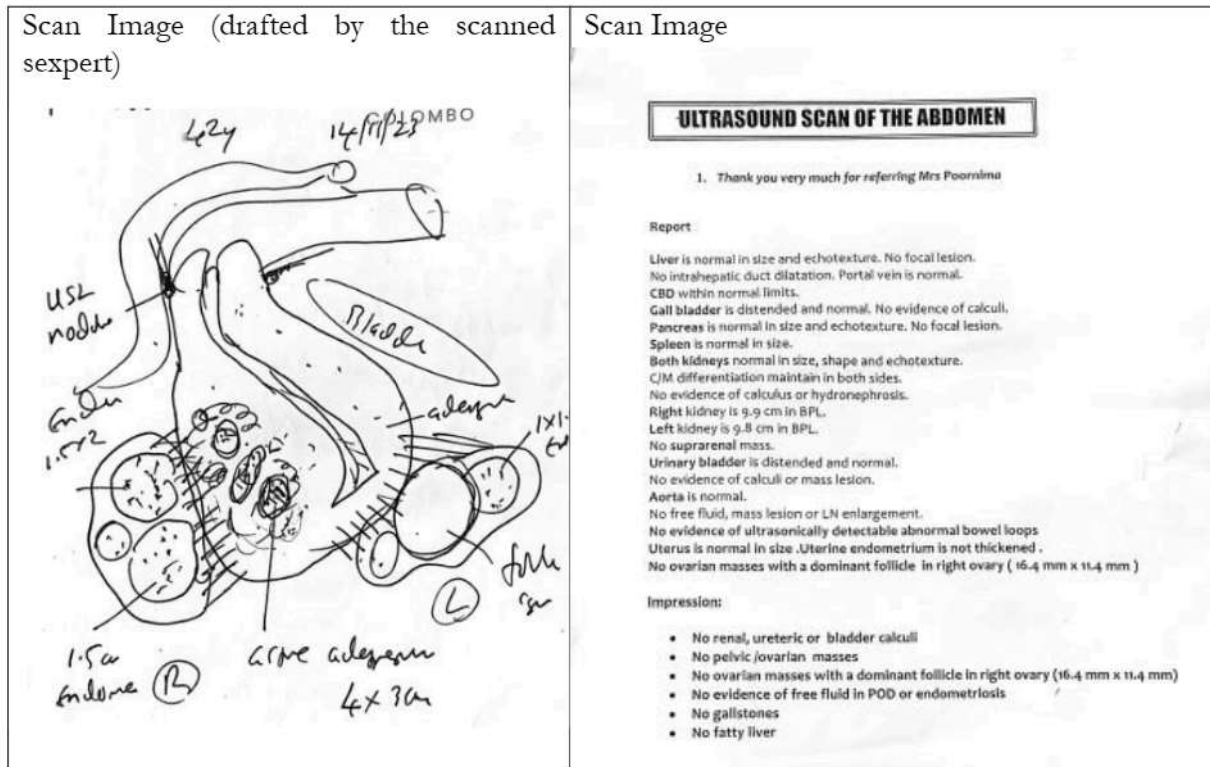


Table 7: Accepted Guna Karma of used oral drugs

Used Oral Drugs	Accepted Guna Karma (Action) related to this patient
<i>Pancamuli lagu Drakshadi Kashaya</i>	<i>Ama Pacana, Vata Pitta Shamaka</i>
<i>Tripal guggul Kashaya</i>	<i>Ama Pacana, Agni Deepana, Anulomana, Karshana, Tridosha shamana</i>
<i>Punarnawashtaka kashaya</i>	<i>Shopa hara, Kapha hara</i>
<i>Madnyashti Nishayugma Kashaya</i>	<i>Vata Pitta Shamana</i>
<i>Tripala kwatha</i>	<i>Agni Deepana, Anulomana</i>
<i>Avipattikara churna</i>	<i>Ama Pacana, Agni Deepana, Anulomana</i>
<i>Nishadi churna</i>	<i>Karshana, Lekhana, Shopa hara</i>
<i>Krishnajeeraka churna</i>	<i>Vedana stapana, agni Deepana, jvaraghna</i>
<i>Tripala churna</i>	<i>Agni Deepana, Anulomana</i>
<i>Chandraprabha vati</i>	<i>Shodana</i>
<i>Kancanara guggulu</i>	<i>Lekhana, Karshana</i>
<i>Arogyavardhani vati</i>	<i>Ama Pacana, Agni Deepana, Medonashaka, Pitta shamana,</i>

Table 8: Accepted Guna of Pancakarma and Local treatments

Pancakarma/ Local Treatment	Accepted Guna (Action) related to this patient
<i>Yoga Vasti</i>	<i>Vata Shamana, Karshana, Lekhana, Anulomana</i>
<i>Matra Vasti</i>	<i>Vata Shamana, Anulomana</i>
<i>Sneha and Sweda</i>	<i>Vata Shamana</i>
<i>Udara Pattu (Upanaba Sweda)</i>	<i>Vata Shamana, Lekhana, Karshana</i>

DISCUSSION:

Improvement of the disease – Patient compliance was well within the three months treatment period. Her vital data maintained at normal range before and after. Her BMI at the initiation point was little high but at the end of treatment weight was reduced and she could able to achieved the normal BMI (table 04). With the analysis of the visual Analogues Scale it was clearly noticed Dysmenorrhoea, Dyspareunia and the pelvic pain was controlled gradually. When the progress compared with the mode of treatment it is clear after the IPD treatment a drastically improvement has achieved. Even though we didn't use any subjective parameter to measure the effect of intervention on quality of life, good compliance, regular clinic attendance and positive outcomes on measured information are witness the improvement of quality of life. The imaging study of the case shows highly encouraging results. Bi lateral ovarian cysts and the adenoma condition was not reported at the after 3months report. As these investigations were done by the expert in imaging who is blind to the study the biasness could be taken as zero.

Rationale of Management -Line of Treatment for this case is developed based on *Yoni Vyapath chikitsa*. *Ayurveda* says that the disorder of yoni does not occur without vitiation of *Vata*, hence pacification of *Vata* should be done by alleviating procedures of *Vata*^[7]. Firstly, proper *Ama pacana* and *Agni Deepana* and *Shodana* treatments were done. After the proper *Shodana* in first two-week treatment regimen case was admitted for Indoor patient Department for two weeks. *Lekhana*, *Karsana* measures were introduced internally and externally under *Shamana*

treatments. *Vata Anulomana*, *Vata Shamana*, *Kapha* and *Pitta Shamana* measures were also adopted. *Panchakarma* and other external procedures were focused to *Pakvashaya* as it is the seat for the disease. It is clear by the VAS scoring, pain (table 05) has drastically reduced after the one month of intervention. The further management was focused to *Samprapthi vigbatana* of the disease. Most of the drugs used for this case contain *Ama pachana* and *Agni Deepana* properties (table 07). *Ama Pacana* and *Agni Deepana* are important treatment bases in *Ayurveda* management. *Ayurveda* considered all diseases are manifested due to *Ama*. *Ama* is predominant of *Kapha* and is produced by *Ajirna* or indigestion. Correctly formed *Dhatu* is responsible for *Bala* or *Ojas*. Mainly *Rasa dhatu* is preserving *Bala/Ojas*^[8]. If *Dhatu* cannot maintain the *Bala* due to accumulation of *Ama*, diseases are manifested. For proper metabolism and gain the benefit of drugs *Ama Pacana* and *Agni Deepana* properties are helpful.

Controlling the *Kapha* and *Pitta dosha*, reacting against the adhesions and control further development of the disease was achieved by *Ama Pacana* and *Agni Deepana* management. Further the proven pharmacological actions of some of the tested drugs could also be taken in to the grant for the effect provided by the therapeutic regimen to the disease. Anti-inflammatory, analgesic activity of the *Punarnavashataka Kashaya*^[8], anti-inflammatory and anti-tumor property of *Chandraprabha vati*^[9] and cytotoxic, antiproliferative property of *Kanchanara gugulu*^[10] would definitely provide antiproliferative effect on adenomyotic foci and endometrium, inhibition of inflammation which is supportive to control the disease.

The panchakarma treatments and the external treatment have played major role in controlling the disease of this case. While treating all gynecological disorder *Vata Shamana* is a must. Among *Pancakarma* procedures *Vasti* is the most beneficial *Karma* which pacifies *Vata Dosha*. Hence, we choose *Vasti Karma* as the main *Shodana* treatment. *Sneha* and *Sweda* act as *Vata Shamana Upakrama* and also act as *Purva karma* for *Vasti* treatment. Considering investigation findings and clinical features this is a *Bahu Dosha* condition. Therefore, doing *Shodana* using *Pancakarma* is a must at this stage [11]. As mentioned, early endometriosis and *Udavarta Yoni Vyapath* etiopathogenesis was related to *Vimargagamana* (Retrograde menstruation). To prevent further *Vimargagamana Vata Anulomana* is a must. Therefore, we used several drugs and treatment procedures having *Anulomana* properties. While selecting drugs for *Vasti*, and oral drugs specially considered there *Karshana* and *Lekhana guna*. Because *Lekhana* and *Karshana Guna* were beneficial for reduced adenomyosis condition and chocolate cysts. [12,13] Further local applications, *Pattu* treatments would improve the blood circulation near to the uterus, wash off the inflammatory materials and support the body to act against the disease while controlling the clinical features. The final results of the ultrasound images and the data of clinical feature assessments prove the efficacy of selected treatment regimen of this case. But to generalized the findings well designed randomized clinical trials are essential.

CONCLUSION:

Comprehensive Sri Lankan traditional medicine and *Ayurveda* treatment modalities are affordable and effective treatment option

for endometriosis and adenomyosis patients. The disease is similar to *Vataja yoni vyapath* mentioned in *Ayurveda*. All the stages of the condition can be explained through *Ayurveda* theory. Considering the dosas and other factors which are involved in their manifestation *Vata anulomana*, *Ama pachana*, *Agni Deepana* treatments were incorporated followed by *Lekhana Karshana* external and internal measures. With the positive outcomes observed by the vital sings, *VAS* scores and imaging results it can be concluded, this case has successfully managed by Sri Lankan traditional and *Ayurveda* treatments.

Limitation of Study:

Most of the Sri Lankan traditional formulas and *Ayurveda* medicines were studied by pilot and case studies, but significant clinical trials have yet to be conducted. As a result, we recommend conducting clinical trials with large number of patients to obtain more scientific evidence-based information.

Declaration of patient consent:

An informed written consent was obtained from the patient for participating in the study and reporting this case in research journal.

Conflict of interest: The author declares that there is no conflict of interest.

Guarantor: The corresponding author is the guarantor of this article and its contents.

Source of support: None

How to cite this article:

Kaumadi Karunagoda, SHK. Deepthika, PK Perera, YAUD Karunarathne. Effect of Sri Lankan Traditional Medicine and *Ayurveda* Management in Endometriosis &

Adenomyosis - A Case Study. *Int. J. AYUSH CaRe.* 2024;8(4):466-474.

<https://doi.org/10.70805/ija-care.v8i4.639>

REFERENCES:

1. World Health Organization. Fact sheet. Available from: <https://www.who.int/news-room/fact-sheets/detail/endometriosis>. [Accessed 2024 Sep 25].
2. Weir E, Mustard C, Cohen M, Kung R. Endometriosis: What is the risk of hospital admission, readmission, and major surgical intervention? *J Minim Invasive Gynecol.* 2005;12(6):486–93.
3. Bulun SE, Yildiz S, Adli M, Chakravarti D, Parker JB, Milad M, et al. Endometriosis and adenomyosis: shared pathophysiology. *Fertil Steril.* 2023;119(5):746–50.
4. Lamceva J, Uljanovs R, Strumfa I. The main theories on the pathogenesis of endometriosis. *Int J Mol Sci.* 2023;24(5):4254–4268.
5. Sharma RK. *Charaka Samhita, Chikitsa Stana 30/25.* Varanasi: Chaukhamba Sanskrit Series; 2017. p. 135.
6. Momenimovahed Z, Salehiniya H, Allahqoli L, Lagana AS, Mazidimoradis A, Moawad G, et al. Effects of herbal compounds on various aspects of endometriosis treatment: A systematic review. *Eur Rev Med Pharmacol Sci.* 2024; 28:3375–83.
7. Sharma RK. *Charaka Samhita, Chikitsa Stana 30/116.* Varanasi: Chaukhamba Sanskrit Series; 2017. p. 159.
8. Sharma PV. *Susrutha Samhita, Sutra Stana 22/19.* Varanasi: Chaukhamba Vishvabharathi; 2013. p. 213.
9. Sharma V. Anti-inflammatory and analgesic activity of Punarnavashtak Kwath, an Ayurvedic formulation. *BLDE Univ J Health Sci.* 2017; 2(1):38-43.
10. Sahoo P, Mahanta NR. Critical analysis on a multipotent drug Chandraprabha Vati: A review article. *IRJAY.* 2022;5(1):105–17.
11. Tomar P, Dey YN, Sharma D, Wanjari MM, Gaidhani S, Jadhav A. Cytotoxic and antiproliferative activity of Kanchnar Guggulu, an Ayurvedic formulation. *J Integr Med.* 2018;16(6):411–7.
12. Murthy KRS, editor. *Ashtanga Hridaya of Vagbhata, Sutra Stana 1/18.* Varanasi: Chowkambha Surabharathi Prakashan; 2009. p. 11.
13. Ushakumari PK, Nagabhushanam G. *Endometriosis.* 3rd ed. Kottakal: Department of Publications, The Arya Vaidyasala; 2005. p.119.